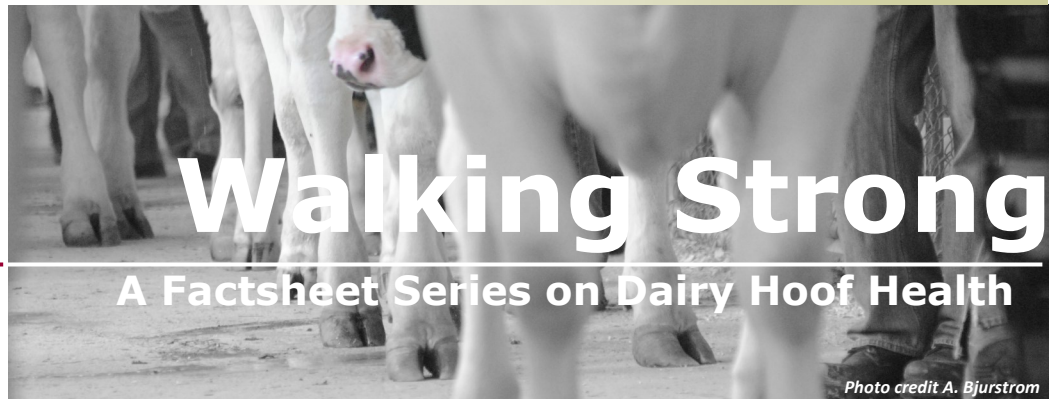

Updated  
Spring 2023



# Proper Foot Wrap Application

**The disease:** Digital dermatitis is one of the most common foot diseases of the dairy cow and can be found in even well managed dairy herds.

It is an infectious disease caused by a family of spiral-like bacteria called *Treponema*. Special attention must be given to this foot disease in order to treat the animals which serve as a reservoir of infection and to reduce the spread of infection.

Cows affected with digital dermatitis are usually easily spotted by the way they walk or behave. They appear to walk on their toes and they shift weight off the infected foot while standing. Lesions can also be spotted by washing the heels in the parlor and using a bright light to identify active lesions.

### Treating Digital Dermatitis:

Footbaths do not cure rather, they are a management practice designed to maintain existing digital dermatitis in an inactive state (Stage M4). Treating infected (Stage M2) digital dermatitis on individual cows reduces the reservoir of infection which in turns reduces the incidence of spreading bacteria to other herd mates.

Digital dermatitis can respond to topical treatment without foot wraps. The lesion

should be wiped clean with a gauze pad or paper towel. An antibiotic powder such as oxytetracycline\* should be applied. Oxytetracycline has resulted in remarkable improvement with the cow showing few, if any, real signs of pain within 24 to 28 hours. A gauze pad held in place by an adhesive bandage is applied to the treated area to ensure the lesion is dry and has contact with the antibiotic powder for a minimum of 30 minutes (see steps to properly apply a foot wrap on page 2).

The prolonged use of foot wraps on individual cows for treatment can cause problems. If applied too tight, additional trauma can occur to the foot or pastern. Apply wraps loosely to reduce the risk of injury. Foot wraps staying on too long can create an environment around the foot which will perpetuate the foot disease, potentially delaying or diminishing healing. The purpose of the wrap is to ensure the lesion is dry and has contact with the antibiotic powder for 30 minutes. Wraps should be removed within 24 hours after application if they have not fallen off.

\*The use of oxytetracycline for treatment of digital dermatitis is considered extra-labeled prescription drug use. The use of this product in this manner must be done through a valid veterinary-client-patient-relationship (VCPR).

### Authored by:

#### Tina Kohlman

Regional Dairy Educator  
Fond du Lac, Sheboygan,  
Ozaukee & Washington Co  
[tina.kohlman@wisc.edu](mailto:tina.kohlman@wisc.edu)  
920.929.3180

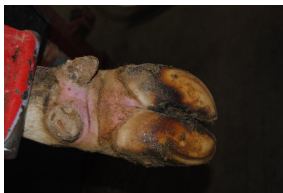#### Aerica Bjurstrom

Regional Dairy Educator  
Kewaunee, Door & Brown Co  
[aerica.bjurstrom@wisc.edu](mailto:aerica.bjurstrom@wisc.edu)  
920.388.7138



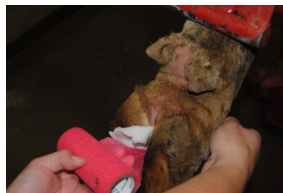Extension  
UNIVERSITY OF WISCONSIN-MADISON

## Proper foot wrap application for treating digital dermatitis

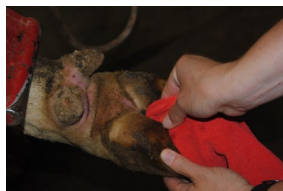


### Step 1:

Properly restrain the foot to minimize the risk of injury to animal or individual.



**Step 7:** Place adhesive wrap in between the toes, in a similar manner as the gauze pad. Hold the free end of the gauze pad with one hand to the front of the foot.



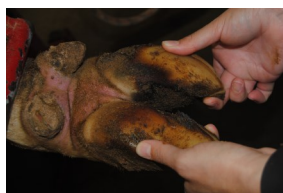### Step 2:

Clean the lesion with a disposable towel or gauze pad.



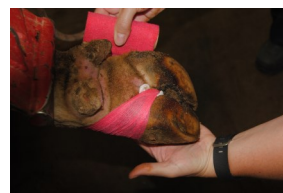### Step 8:

While unwrapping the roll, begin wrapping loosely to the left of the foot making sure the gauze pad remains under the wrap and over the lesion.



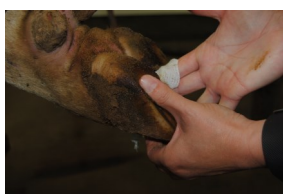
### Step 3:

Inspect the foot for extent of lesions. Record the date, cow number, foot infected, type of lesion, and treatment.




### Step 9:

While still holding the starting end of the bandage on the front of the foot, wrap the bandage over the starting end and continue wrapping the bandage around the front to the foot to the back of the heel. Wrap the bandage around the backside of the foot to secure the gauze pad in place.

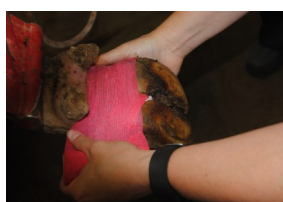

### Step 4:

Place a 4"x 4" gauze pad in between the toes of the foot. Allow the top portion of the gauze to protrude in order to cover the lesion.

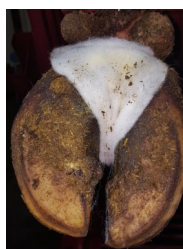


**Step 5:** With curved forceps, open the area between the toes and apply 2 grams oxytetracycline\* powder directly onto the lesion. Gently slide the gauze pad back and forth, working some of the powder in between the toes.



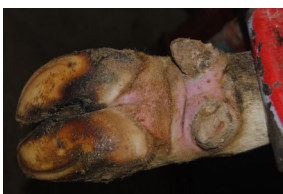### Step 10:

Tear the wrap from the roll. Secure the wrap to the left side of the foot by rubbing the wrap onto itself.



### Step 6:

Cover the antibiotic-covered lesion with the remaining portion of the gauze pad.



### Step 11:

Within 24 hours, remove the wrap and gauze pad from the foot.

*\*The use of oxytetracycline for treatment of digital dermatitis is considered extra-labeled prescription drug use. The use of this product in this manner must be done through a valid veterinary-client-patient-relationship (VCPR).*



Extension

UNIVERSITY OF WISCONSIN-MADISON

An EEO/AA employer, University of Wisconsin-Madison Division of Extension provides equal opportunities in employment and programming, including Title VI, Title IX, the Americans with Disabilities Act (ADA) and Section 504 of the Rehabilitation Act requirements.